

Curcumin Attenuates Oxidative Stress and Inflammatory Response in the Early Phase after Partial Hepatectomy with Simultaneous Intraabdominal Infection in Rats

Daniel Seehofer, M.D.,^{*,1} Anja Schirmeier,^{*} Stig Bengmark, M.D.,[†] Si-Young Ria Cho, M.D.,^{*} Martin Koch, M.D.,[‡] Andri Lederer,^{*} Nada Rayes, M.D.,^{*} Michael D. Menger, M.D.,[§] Peter Neuhaus, M.D.,^{*} and Andreas K. Nüssler, Ph.D.[|]

^{*}Department of General, Visceral, and Transplant Surgery, Charité Campus Virchow, Berlin, Germany; [†]Department of Hepatology and Department Surgery, University College of London, Liver Institute, London, UK; [‡]Department of Pathology, Charité Campus Mitte, Berlin, Germany; [§]Institute for Clinical and Experimental Surgery, University of Saarland, Homburg, Germany; and [|]Department of Trauma Surgery, Klinikum Rechts der Isar, Technical University, Munich, Germany

Submitted for publication June 21, 2008

Background. Curcumin is a nontoxic, hepatoprotective antioxidant. It has been shown to efficiently scavenge oxygen free radicals, increase intracellular glutathione concentrations, and prevent lipid peroxidation in rat hepatocytes. Moreover, it has strong anti-inflammatory effects. In the present study we assessed its effect in a model of liver regeneration impaired by bacterial infections.

Material and Methods. Male Sprague-Dawley rats underwent sham operation, cecal ligation and puncture (CLP), synchronous partial hepatectomy (PH), and CLP or synchronous PH+CLP with perioperative application of curcumin (100 mg per kg bodyweight per d) 48 h before surgery. Rats were sacrificed 24 h after surgery. Liver function was analyzed by measuring the serum albumin, serum bilirubin, and bile production. The local inflammatory response in the liver tissue was evaluated by quantification of TNF- α , IL-6 mRNA, and quantification of IL-1 β by ELISA. In addition, hepatic concentrations of reduced glutathione (GSH) and the oxidized disulfide dimer of glutathione (GSSG) were measured for determination of the redox state.

Results. After simultaneous PH+CLP curcumin significantly reduced the expression of TNF- α and IL-6 mRNA in the liver tissue. The IL-1 β concentration in the liver was also slightly, but not significantly, lower in the curcumin group. A severe depletion of hepatic

glutathione was found in the PH+CLP group. This was reversed by curcumin application, after which the GSH to GSSG ratio increased markedly. The hepatocellular damage, measured by ALT liberation, was significantly lower in the curcumin treated group. The relative liver weight in the curcumin group was significantly higher 24 h after PH+CLP. However, hepatocellular proliferation parameters were not significantly improved by antioxidative treatment with curcumin. Only the Ki-67 index was slightly higher in the curcumin treated PH+CLP group ($14 \pm 3\%$) than in the untreated PH+CLP group ($7\% \pm 3\%$). The hepatocyte density was significantly lower in the curcumin group than in the corresponding untreated group.

Conclusion. In the present model, curcumin revealed significant hepatoprotective effects with stabilization of redox state, reduced liberation of liver enzymes, and attenuated expression of pro-inflammatory cytokines. However, the hepatocellular proliferation was not significantly influenced. © 2010 Published by Elsevier Inc.

Key Words: curcumin; partial hepatectomy; bacterial infections; CLP; glutathione; cytokines; oxidative stress.

INTRODUCTION

Curcumin has been used in Asian medicine for more than 4000 y for the treatment of wounds, tumors, and inflammatory conditions. It is a very potent antioxidant [1] with hepatoprotective activity [2]. For instance,

¹ To whom correspondence and reprint requests should be addressed at Department of General, Visceral, and Transplantation Surgery, Charité Campus Virchow, Augustenburger, Platz 1, D - 13353 Berlin, Germany. E-mail: daniel.seehofer@charite.de.

curcumin pretreatment disclosed protective effects in a rat model of CCl_4 induced acute liver failure [3]. In numerous other studies, curcumin has been shown to scavenge oxygen free radicals [4], prevent lipid peroxidation [5, 6], and increase intracellular glutathione concentrations in rat hepatocytes [7].

Besides its antioxidant potential, curcumin has strong anti-inflammatory effects. Curcumin has been proven to inhibit $\text{TNF-}\alpha$ and IL-6 in several experimental models [8, 9] and to reduce the production of IL-1 β [10] and TGF- β [11], two important inhibitors of liver regeneration. Also, an inhibition of endotoxin induced activation of NF- κ B with resultant reduction of inducible nitric oxide synthase (iNOS) and cyclooxygenase-2 (COX-2) activity has been reported [12].

Bacterial infections are accompanied by early and augmented cytokine liberation and increased oxidative stress. Although IL-6 expression is essential during the regeneration process of the liver, early and increased elevation of IL-6 production has been shown to inhibit cell-cycle progression after liver resection in mice [13]. We have previously shown that liver regeneration after major hepatectomy is significantly impaired during severe bacterial infections [14]. Curcumin might influence this delay in the regeneration process through modification of the inflammatory response and antioxidative effects. In a previous study [15], we have demonstrated a synergistic effect of curcumin and erythropoietin in a model of liver resection plus cecal ligation and puncture, whereas erythropoietin as monotherapy was not effective in this setting. The present experimental series reports on the effect of curcumin application alone on oxidative stress, inflammatory response, and liver regeneration in the same model.

MATERIAL AND METHODS

Experimental Groups

Male Sprague Dawley rats (Winkelmann, Bochum, Germany) with 200 to 300 g bodyweight were used for all experiments, which were performed in accordance with the German legislation on the protection of animals.

Rats were randomly divided in four experimental groups: sham operation, cecal ligation and puncture, 70% partial hepatectomy (PH) plus synchronous CLP, and PH plus CLP with perioperative curcumin application. Each group consisted of six animals. A 100 mg pure curcumin (Sigma-Aldrich, Steinheim, Germany) per kilogram bodyweight was administered by gavage. Curcumin was dissolved in 1.5 mL commercially available enteral feeding solution and given 48 h, 24 h, and 30 min before surgery as well as 6 h after surgery.

Surgery

In the sham-operated group the liver was separated from its ligamentous suspension and the cecum was gently moved. During partial hepatectomy (PH) 70% of the liver tissue was removed by standardized resection of the middle and left lateral lobe. For cecal ligation and puncture (CLP), a stool reservoir of 1 cm diameter was created

from the distal cecum by placing a ligature. Afterwards the reservoir was punctured once using a 22 gauge needle and a small amount of stool was squeezed out to ensure wound patency. This technical specification of CLP is well tolerated in combination with major liver resection [14]. After surgery, 5 mL sterile isotonic saline was injected subcutaneously together with metamizol plus tramadol for pain relief. Rats were sacrificed after 24 h and blood and tissue samples were collected.

Cytokine Measurements

$\text{TNF-}\alpha$ and IL-6 mRNA-expression in the liver tissue were determined by reverse transcriptase PCR (rt-PCR) and quantified by densitometry. Frozen liver tissue samples were thawed, the total RNA was extracted, and converted to first-strand cDNA. The generated cDNA was subjected to PCR amplification using specific primers for the respective genes on a thermal cycler. The following primers were used: β -actin (antisense 5'ACC CAC ACT GTG CCC ATC TA'3, sense 5'CGG AAC CGC TCA TTG CC '3), $\text{TNF-}\alpha$ (antisense 5' GGA TGA ACA CGC CAG TCG CC '3, sense 5' CGA GTG ACA AGC CCG TAG CC 3'), and IL-6 (antisense 5'GGT AGA AAC GGA ACT CCA GAA GAC '3 sense 5'GGA ACG AAA GTC AAC TCC ATC TGC '3). PCR products were fractionated using agarose electrophoresis, stained with ethidium bromide, and visualized using UV light. Documentation and digitalization for further densitometry analysis was performed using a gel documentation system. The quantitative densitometric assessment was supported by commercially available software (UN-SCAN-IT gel Version 5.1; Silk Scientific, Orem, UT). The obtained values of the individual samples were normalized by division of the β -actin signal.

Hepatic levels of IL-1 β levels were determined using a commercially available sandwich ELISA-kit (Quantikine Immunoassay; R and D Systems, Minneapolis, MN) as described previously [14].

Tissue Glutathione Measurement

The tissue concentration of total glutathione as well as the oxidized disulfide dimer of glutathione (GSSG) were measured. From this the concentration of reduced glutathione (GSH) and the GSH to GSSG ratio were calculated. Glutathione concentrations were determined by a slightly modified method described by Baker *et al.* [16] using snap frozen liver samples. Briefly, total glutathione representing reduced GSH plus GSSG was assayed using an enzymatic recycling procedure in which reduced GSH was sequentially oxidized by 5,5'-dithiobis-(2-nitrobenzoic-acid) (DTNB; Sigma, St. Louis, MO) to GSSG, which is then reduced by NADPH back to GSH in the presence of glutathione reductase to react again with DTNB. The absorbency was measured spectrophotometrically at 405 nm. Results were expressed as nmol per mg of protein.

Histologic Investigation

For histomorphologic analysis, a paraffin embedded sample of the right liver lobe was cut in 4 μ m sections and stained with hematoxylin and eosin (HE). Sections were compared regarding their inflammatory activity, hepatocellular damage, and steatosis.

Regeneration Parameter

The mitotic index was determined in HE sections and calculated per 2000 hepatocytes. After *in vivo* labeling with Bromo-deoxy-uridine (100 mg BrdU per kg bodyweight, Roche, Germany), paraffin sections were stained using a commercially available detection kit (Bromo-deoxy-uridine Labeling and Detection Kit II, Roche, Germany) and the BrdU index was calculated. The total number of proliferating hepatocytes was quantified by Ki 67 immunostaining as described in detail before [14].

Statistical Analysis

All values are given as mean and standard error of mean (SEM). Data were analyzed for normal distribution and equality of variance, and differences were then calculated by the Student's *t*-test for unpaired variables. Differences between the groups underwent a *post hoc* pairwise comparison using the Tukey test. Differences were considered significant if *P* was less than 0.05. All statistical analyses were performed with SPSS 14.0 (SPSS Inc., Chicago, IL).

RESULTS

Inflammatory Parameters

Expression of the key proinflammatory cytokines was markedly attenuated by curcumin treatment. TNF- α expression was significantly higher after CLP alone and after PH+CLP than in the sham operated group. Curcumin treatment reduced TNF- α expression significantly (Fig. 1). Comparable results were obtained for IL-6 expression in the liver tissue (Fig. 2). Quantification of IL-1 β in the liver tissue revealed slightly lower concentrations in the curcumin treated group than in the untreated group, which was, however, not statistically significant (Fig. 3).

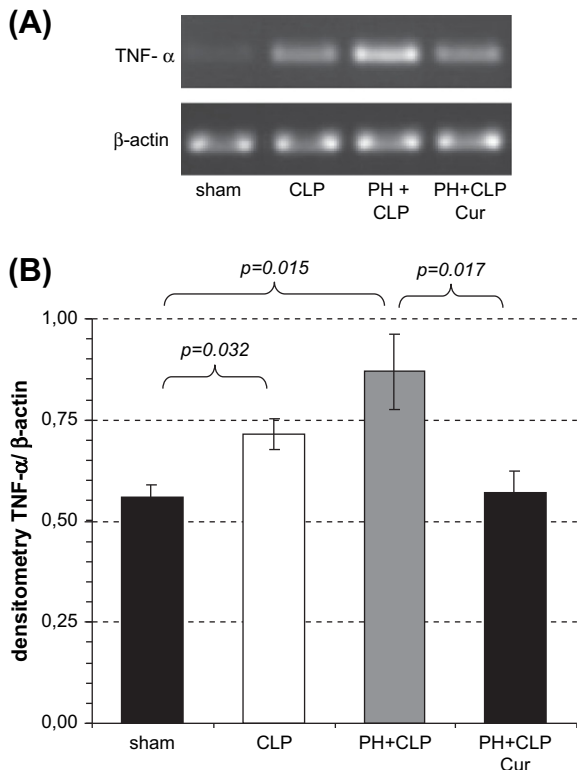


FIG. 1. TNF- α in the liver tissue (A), representative rt-PCR of TNF- α in the liver tissue and (B) densitometric analysis of TNF- α mRNA expression in the liver tissue normalized by β -actin (values of significant differences are indicated).

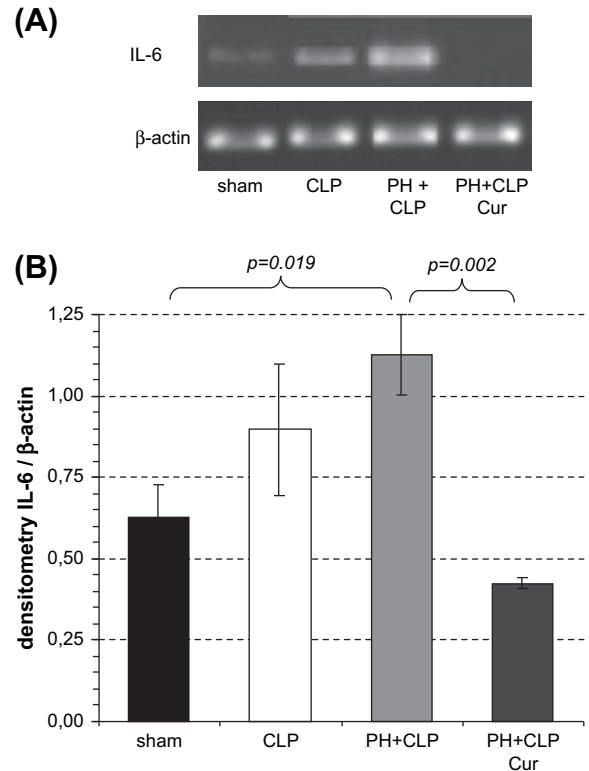


FIG. 2. IL-6 in the liver tissue (A), exemplary rt-PCR of IL-6 in the liver tissue and (B) densitometric analysis of IL-6 mRNA expression in the liver tissue normalized by β -actin, (*P* values of significant differences are indicated).

Glutathione

CLP was followed by severe depletion of hepatic glutathione. The concentrations of total and reduced glutathione (GSH) were low in the untreated CLP groups. Curcumin treatment markedly increased the hepatic

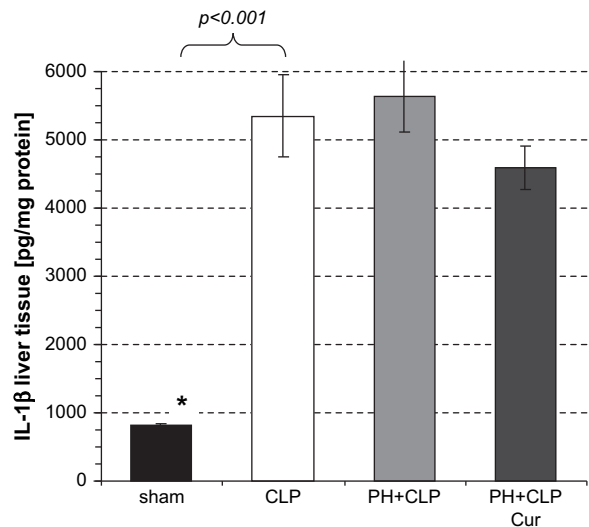


FIG. 3. Concentrations of IL-1 β in the liver tissue (**P* < 0.001 versus all other groups).

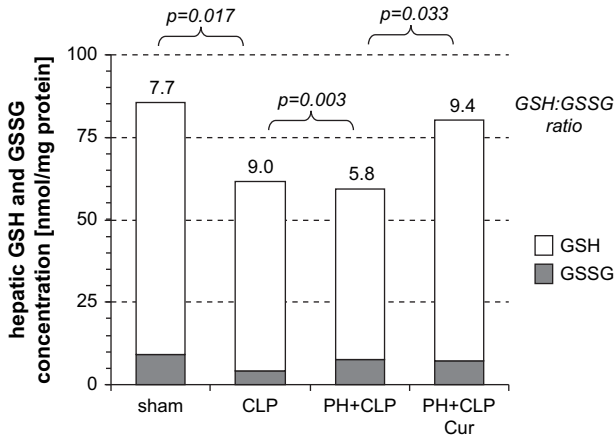


FIG. 4. Hepatic reduced glutathione (GSH) and oxidized glutathione (GSSG) concentrations and calculated ratio of GSH to GSSG as marker of cellular redox state (*P* values of significant differences in the GSH:GSSG ratio are indicated).

GSH concentration and the GSH to GSSG ratio after PH+CLP (Fig. 4).

Hepatocellular Damage and Liver Function

ALT activity in the serum (84 ± 11 U/L) did not increase with CLP alone compared with the sham operated group (67 ± 4 U/L). In contrast, liver enzymes were markedly elevated after PH + CLP. The ALT liberation was significantly reduced by curcumin application (747 ± 67) compared to the untreated group (1716 ± 255 U/L, Fig. 5). Histomorphologic evaluation revealed no relevant inflammatory activity or necrosis in any of the groups. Similar microvesicular fatty changes were seen in both PH+CLP groups. Liver func-

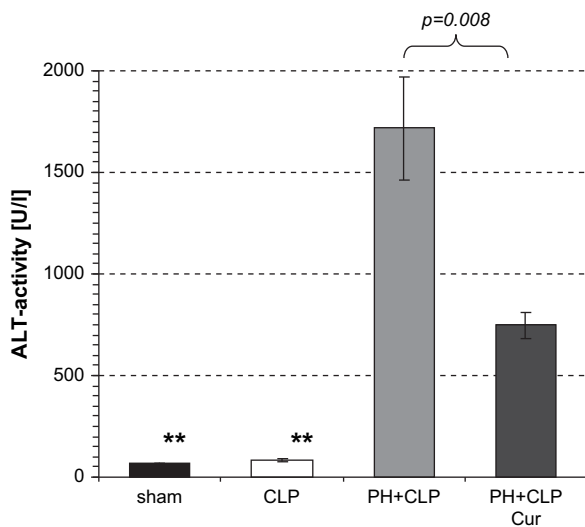


FIG. 5. Serum ALT-activity as marker of hepatocellular damage (*P*-values of significant differences in the GSH:GSSG ratio are indicated; ***P* < 0.01 versus both PH+CLP groups).

tion measured by total serum bilirubin, serum albumin, and bile flow was impaired, but not different in the PH+CLP groups with and without curcumin therapy.

Liver Regeneration

The relative liver weight was significantly higher in the curcumin treated PH+CLP group than in the untreated group (Fig. 6). However, no significant different regeneration markers were observed in the PH+CLP groups with and without curcumin. The mitotic index and the BrdU labeling index were equal in both groups (data not shown), and the relative number of Ki-67 positive hepatocytes was only slightly higher in the curcumin treated group (Fig. 7). However, the hepatocyte density was significantly lower after curcumin application, indicating hepatocellular hypertrophy in this group (Fig. 8).

DISCUSSION

Clinical studies have shown that bacterial infections are a risk factor for liver failure and increased mortality after major hepatectomy [17] or living related liver transplantation [18]. This might be based on several mutual interactions between infections and liver regeneration. On the one hand, reduction of liver mass is associated with a reduced capacity in the defense of bacterial infections [19]; severe infections might be followed by disturbances in liver regeneration [14] and metabolic function of the liver [20].

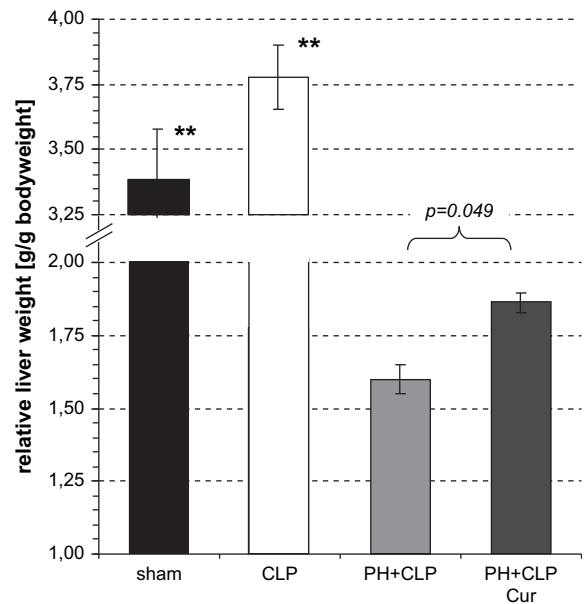


FIG. 6. Relative liver weight 24 h after surgery (*P* values of significant differences are indicated; ***P* < 0.001 versus both PH+CLP groups).

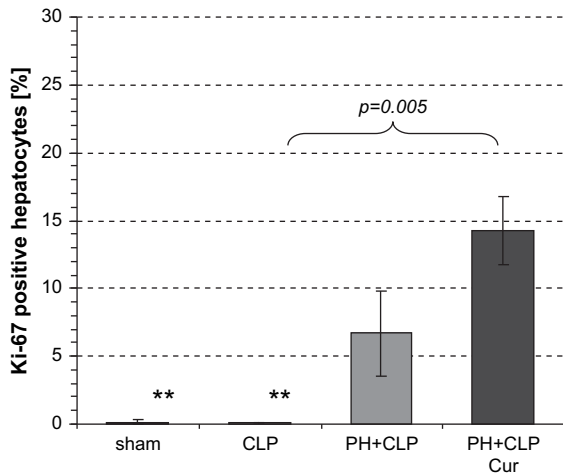


FIG. 7. Percentage of Ki67 positive hepatocytes (*P* values of significant differences are indicated; ***P* < 0.05 versus both PH+CLP groups).

Sepsis or severe bacterial infections are accompanied by excessive liberation of proinflammatory cytokines and serious oxidative stress. This can be diminished by application of antioxidants like α -tocopherol [21] or N-acetylcysteine [22].

In the present study, curcumin lowered the expression of pro-inflammatory cytokines and attenuated oxidative stress after simultaneous major hepatectomy and CLP. The experimental model utilized in this study is not comparable to sepsis-induced liver failure but resembles infectious complications after major liver surgery. Whereas after minor liver resections or anatomic hemihepatectomies, severe intraabdominal infections are rare, they represent a relevant complication

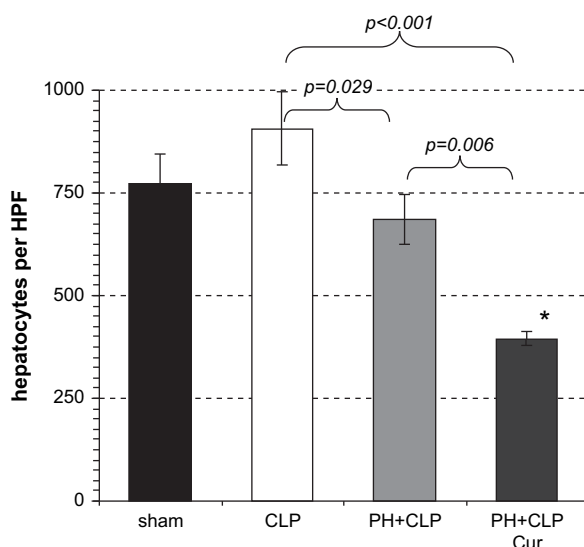


FIG. 8. Mean number of hepatocytes per HPF determined in the BrdU labeled slides in the different groups (*P* values of significant differences are indicated, **P* = 0.004 versus sham operation).

after extended hepatic resections with simultaneous bilio-enteric anastomosis or after living related liver transplantation. For example, in a large single center series reporting on 208 recipients with living related liver grafts, a total of 132 intra-abdominal infections were observed and associated with an increased mortality [18]. Similarly, in a series of 100 liver resections for hilar cholangiocarcinoma, 19% of the patients were diagnosed with an intra-abdominal abscess postoperatively [23].

However, despite effective attenuation of oxidative stress and proinflammatory responses, curcumin did not improve liver regeneration in the present model. However, in the curcumin group a slightly increased Ki-67 index was observed. Previous experiments have shown that CLP induced infections after liver resection significantly compromise liver function during the first 48 h [14]. This depressed liver function might be a limiting factor for the highly energy-dependent process of liver regeneration.

Another fact that has to be taken into consideration is that curcumin is a potent inhibitor of cell cycle progression at the level of the G2/M transition point [24]. Our group has shown in coeval experiments that even normal liver regeneration after 70% partial hepatectomy in rats is inhibited by application of curcumin, mainly at the level of the G2/M transition point [25]. This might also contribute towards the unchanged depression of liver regeneration despite improvements of the inflammatory response and oxidative stress.

One limitation of the present model is that only the early phase of liver regeneration was studied. Differences after 24 h cannot be excluded. However, similar studies showed that differences in the regeneration process in rats are only observed at early time points [14].

Taken together, curcumin revealed significant protective effects resulting in stabilization of redox state, attenuated expression of liver enzymes, lower mRNA expression of pro-inflammatory cytokines, and hepatocellular hypertrophy. However, despite its antioxidant and anti-inflammatory activity, liver regeneration could not be significantly improved by curcumin treatment.

ACKNOWLEDGMENTS

This study was supported by a grant from the Deutsche Forschungsgemeinschaft (Se1694/2-1) (to D.S.).

REFERENCES

1. Khopde SM, Priyadarsini KI, Venkatesan P, et al. Free radical scavenging ability and antioxidant efficiency of curcumin and its substituted analogue. *Biophys Chem* 1999;80:85.
2. Bengmark S. Curcumin, an atoxic antioxidant and natural NFkappaB, cyclooxygenase-2, lipooxygenase, and inducible

- nitric oxide synthase inhibitor: A shield against acute and chronic diseases. *JPEN J Parenter Enteral Nutr* 2006;30:45.
3. Park EJ, Jeon CH, Ko G, et al. Protective effect of curcumin in rat liver injury induced by carbon tetrachloride. *J Pharm Pharmacol* 2000;52:437.
 4. Reddy AC, Lokesh BR. Studies on the inhibitory effects of curcumin and eugenol on the formation of reactive oxygen species and the oxidation of ferrous iron. *Mol Cell Biochem* 1994;137:1.
 5. Reddy AC, Lokesh BR. Studies on spice principles as antioxidants in the inhibition of lipid peroxidation of rat liver microsomes. *Mol Cell Biochem* 1992;111:117.
 6. Wei QY, Chen WF, Zhou B, et al. Inhibition of lipid peroxidation and protein oxidation in rat liver mitochondria by curcumin and its analogues. *Biochim Biophys Acta* 2006;1760:70.
 7. Dickinson DA, Iles KE, Zhang H, et al. Curcumin alters EpRE and AP-1 binding complexes and elevates glutamate-cysteine ligase gene expression. *FASB J* 2003;17:473.
 8. Cho JW, Lee KS, Kim CW. Curcumin attenuates the expression of IL-1beta, IL-6, and TNF-alpha as well as cyclin E in TNF-alpha-treated HaCaT cells; NF-kappaB and MAPKs as potential upstream targets. *Int J Mol Med* 2007;19:469.
 9. Gukovsky I, Reyes CN, Vaquero EC, et al. Curcumin ameliorates ethanol and nonethanol experimental pancreatitis. *Am J Physiol Gastrointest Liver Physiol* 2003;284:85.
 10. Gaddipati JP, Sundar SV, Calemine J, et al. Differential regulation of cytokines and transcription factors in liver by curcumin following hemorrhage/resuscitation. *Shock* 2003;19:150.
 11. Gaedeke J, Noble NA, Border WA. Curcumin blocks multiple sites of the TGF-beta signaling cascade in renal cells. *Kidney International* 2004;66:112.
 12. Surh YJ, Chun KS, Cha HH, et al. Molecular mechanisms underlying chemo-preventive activities of anti-inflammatory phytochemicals: Downregulation of COX-2 and iNOS through suppression of NF-kB activation. *Mutation Research* 2001;243:480.
 13. Sun R, Jaruga B, Kulkarni S, et al. IL-6 modulates hepatocyte proliferation via induction of HGF/p21cip1: regulation by SOCS3. *Biochem Biophys Res Commun* 2005;338:1943.
 14. Seehofer D, Stockmann M, Schirmeier A, et al. Intraabdominal bacterial infections significantly alter regeneration and function of the liver in a rat model of major hepatectomy. *Langenbeck's Arch Surg* 2007;392:273.
 15. Seehofer D, Neumann UP, Schirmeier A, et al. Synergistic effect of erythropoietin but not G-CSF in combination with curcumin on impaired liver regeneration in rats. *Langenbecks Arch Surg* 2008;393:325.
 16. Baker MA, Cerniglia GJ, Zaman A. Microtiter plate assay for the measurement of glutathione and glutathione disulfide in large numbers of biological samples. *Anal Biochem* 1990;190:360.
 17. Wang X, Andersson R, Soltesz V, et al. Bacterial translocation after major hepatectomy in patients and rats. *Arch Surg* 1992;127:1101.
 18. Kim YJ, Kim SI, Wie SH, et al. Infectious complications in living-donor liver transplant recipients: a 9-year single-center experience. *Transpl Infect Dis* 2008; DOI 10.1111/j.1399-3062.2008.00315.x.
 19. Schindl MJ, Redhead DN, Fearon KC, et al. Edinburgh Liver Surgery and Transplantation Experimental Research Group (eLISTER). The value of residual liver volume as a predictor of hepatic dysfunction and infection after major liver resection. *Gut* 2005;54:289.
 20. Wang P, Ba ZF, Chaudry IH. Hepatic extraction of indocyanine green is depressed early in sepsis despite increased hepatic blood flow and cardiac output. *Arch Surg* 1991;126:219.
 21. Konukoglu D, Iynem H, Ziylan E. Antioxidant status in experimental peritonitis: Effects of alpha tocopherol and taurolin. *Pharmacological research* 1999;39:247.
 22. Delvin J, Ellis A, McPeake J, et al. N-acetylcysteine improves indocyanine green extraction and oxygen transport during hepatic dysfunction. *Crit Care Med* 1997;25:236.
 23. Nagino M, Kamiya J, Arai T, et al. One hundred consecutive hepatobiliary resections for biliary hilar malignancy: Preoperative blood donation, blood loss, transfusion, and outcome. *Surgery* 2005;137:148.
 24. Park C, Kim GY, Kim GD, et al. Induction of G2/M arrest and inhibition of cyclooxygenase-2 activity by curcumin in human bladder cancer T24 cells. *Oncol Rep* 2006;15:1225.
 25. Seehofer D, Schirmeier A, Bengmark S, et al. Inhibitory Effect of Curcumin on early liver regeneration following partial hepatectomy in rats. *J Surg Res*, in press.